

# Laparoscopic Cholecystectomy Lower Thoracic Spinal Anesthesia. A retrospective Study with 505 Patients

## ABSTRACT

**Background:** In our group, after a study showing that spinal anesthesia is safe when compared with general anesthesia, spinal anesthesia has been the technique of choice for this procedure. This is a retrospective study with patients undergoing laparoscopic cholecystectomy under thoracic spinal anesthesia.

**Methods:** A total of 505 laparoscopic cholecystectomy patients operated under spinal anesthesia were included in this study. Spinal anesthesia was between T8 to T11, with a 27G cutting point or pencil tip in lateral or sitting. Spinal anesthesia was performed with two doses of 0.5% bupivacaine hyperbaric plus 25 µg of fentanyl, until reaching the sensitive level of T3. We evaluated the demographics, analgesia, and degree of motor block, incidence of paresthesia, bradycardia, hypotension, anesthesia success and neurological complications.

**Results:** All 505 patients developed spinal. Neither the dose of hyperbaric solution of 0.5% bupivacaine nor the addition of fentanyl affected the onset of sensory block. The duration of sensory block was greater than the motor block with hyperbaric solution. Bradycardia occurred in 16 (3.1%) patients, and was not correlated with the level of thoracic puncture. Hypotension occurred in 82 (16.2%), with no significant association with the dose of local anesthetic. None of the 505 patients had the maximum degree of lower limb motor block, with significant difference in terms of dose. Paresthesia was observed in 28 (5.5%) without significant difference between needles. All paresthesias were transient and without residual sequelae.

**Conclusion:** The beginning of the block is fast regardless of the solution used. By providing a sensory block of longer duration than the motor block hyperbaric bupivacaine is reflected in a better indication. Thoracic spinal anesthesia provides excellent anesthesia for lower limb orthopedic surgery, without neurological sequelae.

**Keywords:** Thoracic Spinal Anesthesia, Complications, Local Anesthetic, Hyperbaric Bupivacaine, Fentanyl.

## Introduction

Laparoscopic cholecystectomy (LC) was introduced as a surgical technique in 1988, and since then it has been considered the procedure of choice for the management of symptomatic cholelithiasis [1]. Most of the time and in many hospitals the LC is performed under general anesthesia (GA). A recent meta-analysis showed that spinal anesthesia as the sole anesthesia technique is feasible, safe for elective LC [2]. In none of the various articles consulted was the LC not performed on an emergency basis.

In patients with intermediate predictors of surgical risk, lumbar spinal anesthesia (LSA) was used in combination with ketamine and propofol sedation and was shown to be safe and efficient

[3]. In a study comparing lumbar puncture with 15 mg of 0.5% hyperbaric bupivacaine with thoracic puncture and two doses of 10 and 7.5 mg of the same substance in 369 patients, showed that LC can be performed successfully under spinal anesthesia with low-pressure pneumoperitoneum of CO<sub>2</sub>, and that low-dose thoracic spinal anesthesia (TSA) provides better hemodynamic stability, less hypotension, and shorter duration of sensory and motor blockade than LSA with conventional doses [4-6].

TSA has several advantages over GA for LC. These advantages include that patients remain awake and oriented at the end of the procedure, with the use of hyperbaric solution plus fentanyl, and use of an intraperitoneal anesthetic site, providing less postoperative pain and the ability to walk and earlier than patients who received LSA or GA [4-6].

We recently retrospectively published 1,406 TSA with different clinical specialties with the main objective to evaluate the incidence of paresthesia and neurological complications, as well as cardiocirculatory changes after TSA [7]. This study showed that TSA is safe and without neurological sequelae, with a puncture between T8 and T11.

In this retrospective study, we found 505 patients undergoing TSA for LC. The aim of this study with these patients is to report the experience with the use of spinal anesthesia with low doses of hyperbaric 0.5% bupivacaine and thoracic puncture, associated with 25 µg of fentanyl, low gas pressure to obtain pneumoperitoneum, injection of local anesthetic immediately after the introduction of gas and the cardiocirculatory and pulmonary alterations, and complications neurological [7].

## Methods

The study was approved by the Ethics Committee (Number 5684/2009) and was a retrospective study carried out in several hospitals. All TSA for LC were recorded in an Excel spreadsheet for further study. Due to the fact that the study was retrospective, the Free and Informed Consent Term was released.

All patients eligible for LC routinely and non-emergency was offered as the first option to TSA. Patients who preferred GA or had any contraindication to spinal anesthesia were operated under GA. All patients were informed about the possibility of converting to GA with tracheal intubation. All anesthetics were performed by the same anesthesiologist and laparoscopic surgeries by the same surgical team, consisting of three surgeons.

All patients received a pre-anesthetic visit by the anesthesiologist and the entire procedure was informed, but no pre-anesthetic medication was administered either orally or by muscle. The monitoring used in all patients was ECG continuously in the CM5 lead, non-invasive blood pressure, oxygen saturation and expired CO<sub>2</sub> through the capnograph placed in the nose, and all data were recorded at 5-minute intervals until the incision and afterwards every 10 minutes.

An 20G catheter was inserted in the left hand for hydration and administration of drugs. Initially, 500 mL of Ringer's lactate were infused for the administration of cephalosporin 2 g, ranitidine 50 mg, omeprazole 40 mg, dexamethasone 10 mg, ondansetron 8 mg, and metoclopramide 10 mg before the spinal anesthesia. The nasogastric or orogastric tube was not inserted after spinal anesthesia and the need for its use during surgery was evaluated.

After infusion of 500 ml of lactated Ringer's and all medications inside, patients received supplemental oxygen via the nasal cannula at a rate of 3 l/min. Fentanyl (1 µg/kg) and midazolam (1 mg) were given before spinal anesthesia. After asepsis and antisepsis with 70% alcohol or 0.5% alcohol chlorhexidine, the patients were placed in left lateral decubitus or sitting, we performed a puncture of the subarachnoid space through a median or paramedian with a 27G cut needle without introducer or 27G pencil needle with an introducer (20G) between the T8 to T11 interspaces. Free flow of CSF confirmed the position of the needle into the subarachnoid space. All patients received a spinal fentanyl 25 µg in 1 mL syringe before injection of local anesthetic. According to the description of the type of surgical procedure by the surgeon, doses of 7.5 mg or 10 mg of 0.5% hyperbaric bupivacaine were administered in a 3 ml syringe. After the spinal injection, the patients were placed in a supine position, and their heads were tilted down 20o-30o, until reaching the sensitive level of T3, this time being timed.

This retrospective study of patients undergoing TSA for LC were evaluated the following parameters: needle types, needle insertion, puncture position (sitting or lateral decubitus), thoracic puncture level, presence of cerebrospinal fluid (CSF) in the needle hub, type of anesthetic, latency, motor block, incidence of bradycardia and hypotension, paresthesia (duration) and neurological complications.

The standard laparoscopic technique was used in all patients with one modification, i.e., after visualization of the abdomen using the camera, lidocaine 1% 20 ml or bupivacaine 0.25% 20 ml was sprayed under the right side of the diaphragm through a 22G spinal needle inserted below the lower border of the tenth rib. If the patient still complained of shoulder pain after spraying with local anesthetic would be administered 50 µg of fentanyl. The conversion criteria were: the need to empty the stomach probe, any organ damage, bleeding difficult to control, or if the patient was dissatisfied with TSA at any stage of the procedure.

The data researched during the surgical procedure were: time of use of gas for pneumoperitoneum, need to increase the pressure above 8 mmHG, need to use a nasogastric tube, shoulder pain, nausea and vomiting, discomfort, surgical time of the start of TSA and end of procedure and need for conversion to GA. We also evaluated the time for the sensitive block to reach the T3 dermatomal level, the degree of motor block of the lower limbs (grade 0, 1, 2 and 3), the time to regression of sensory and motor block were also recorded. At the end of the surgery, the trocar entry holes were infiltrated with 0.5% levobupivacaine for analgesia, and were evaluated the ability of the patient to move to the stretcher unaided.

Hypotension was defined as a decrease of more than 30% from the baseline systolic arterial blood pressure and treated with IV boluses of 2 mg ethilephrine. Bradycardia was defined as heart rate <50 bpm (beat per minute) and treated with atropine 0.50 mg. The numbers of hypotensive and bradycardic episodes were recorded. Anxiety was treated with midazolam 1 mg and recorded the total dose.

All patients received 200 ml of maltodextrin in the PACU and intravenous hydration was withdrawn, being taken to the room. Analgesia was performed via the veins with ketoprofen 100 mg every 8 hours and dipyrone 1.5 g every 4 hours. Other post operative events potentially related to either the surgical or anesthetic procedure, i.e., discomfort, nausea and vomiting, shoulder pain, urinary retention, pruritus, headache, or other neurologic sequelae, were also recorded. All patients were followed on the 1st, 3rd and 7th postoperatively up by telephone to check for neurological complications.

## Statistical analysis

For quantitative variables, we used the Kruskal-Wallis test for independent samples and the Wilcoxon test for paired samples. For comparison between groups was used Chi-square test (X<sup>2</sup>) and Fisher's exact test. The level of significance throughout the study was 5%.

## Results

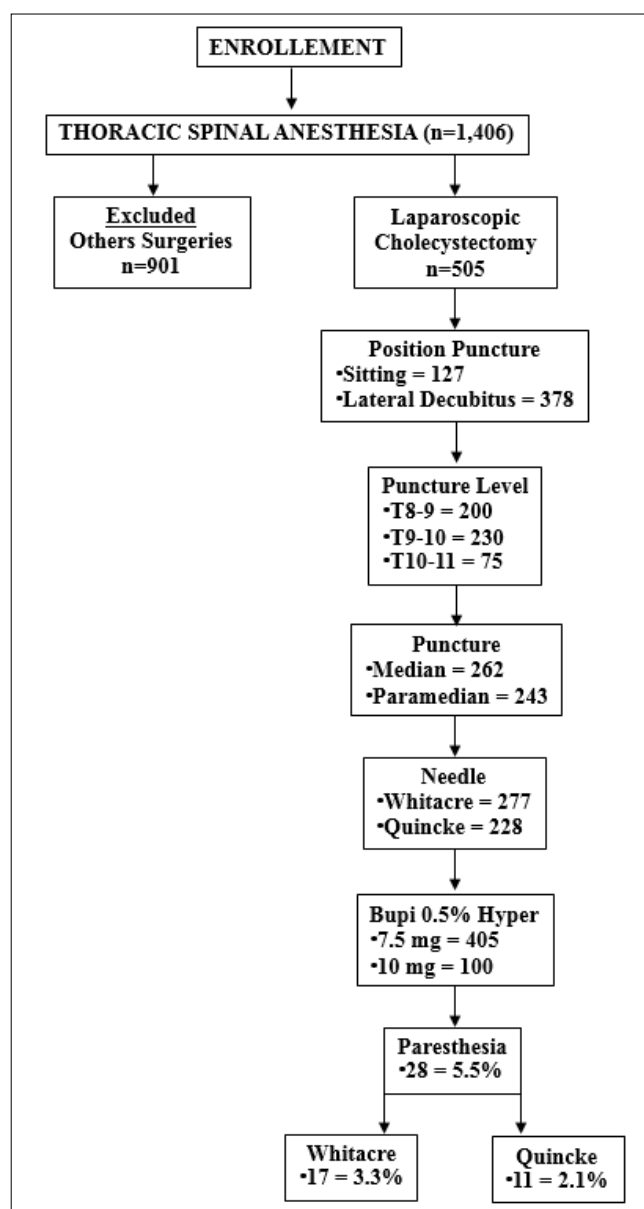
One thousand four hundred patients submitted to TSA were retrospectively reviewed. Of these 1,406 patients, 505 patients undergoing LC were being selected for this study. The remaining 901 patients who underwent several other types of surgery and who underwent TSA surgery were excluded (Figure1). All the 505 patients developed spinal anesthesia, and there was no thoracic

puncture failure, after the appearance of CSF. Demographic data are listed in Table 1.

**Table I. Demographic data (Mean±DP) who underwent TSA, and cholecystitis and abdomen submitted to previous surgery (n/%).**

Variables	Group 7.5	Group 10	P-Value
Number Patients	405	100	-
Age (y)	40.62±13.11	41.00±12.90	0.6449 *
Weight (kg)	70.46±12.56	71.00±11.02	0.4318 *
Height (cm)	163.55±8.76	164.00±8.46	0.8558 *
Gender: F / M	299 / 106	78 / 22	0.4423 **
ASA: I / II	208 / 197	51 / 49	1.0000 **
Cholecystitis	32 (7.9%)	8 (8%)	1.0000 **
Previous Surgeries	62 (15,3%)	15 (15%)	1.0000 **

F= female; M=male \*: Kruskal-Wallis test \*\*: Fisher's exact test



**Figure 1: Consort Flow Diagram**

Due to the meeting at the pre-anesthetic visit before surgery with the surgeons, who predicted surgical difficulties, the dose of 7.5 mg of 0.5% hyperbaric bupivacaine plus 20 µg of fentanyl, which is usually used in most patients, was increased to 10 mg of same solution with the opioid. The onset of sensory block ranged from 0:36 to 1:44 minutes, with a mean of 0:58±0:10 minutes, regardless of the dose of 7.5 mg or 10 mg of 0.5% hyperbaric bupivacaine with 25 µg of fentanyl. Neither the dose of hyperbaric solution of 0.5% bupivacaine nor the addition of fentanyl affected the onset of sensory block.

Bradycardia occurred in 16 (3.1%) patients, 13 patients (3.2%) with a dose of 7.5 mg and 3 patients with a dose of 10 mg of 0.5% hyperbaric bupivacaine. Using Fisher's exact test showed that there is no significant association with the dose of local anesthetic hyperbaric bupivacaine (p-value=1.000). The incidence of bradycardia was not correlated with the level of thoracic puncture from T8 to T11 (p-value=0.90518).

Hypotension occurred in 82 (16.2%) of the patients, 77 with a dose of 7.5 mg and 15 with 10 mg of 0.5% hyperbaric bupivacaine, with no significant association with the dose of local anesthetic (p-value=0.3519).

None of the 505 patients had the maximum degree of lower limb motor block. Of the 505 patients, 315 had motor block degree 1 and 191 had motor block degree 2, with significant difference in terms of dose (p-value<2.2e 16).

The mean duration of motor block was 1:31±0:20 hours, much shorter than the mean duration of sensory block which was 2:52±0:27 hours, being significantly smaller (p-value < 2.2e-16) (Table III). However, increasing the dose of 0.5% hyperbaric bupivacaine from 7.5 mg to 10 mg (33% higher) did not change the duration of sensory and motor blocks in the postoperative evaluation. However, the association with 25 µg of fentanyl, allowed a quality of analgesia up to 6 hours later.

**Table II: Characteristics of Thoracic Spinal Anesthesia**

Parameters	Group 7.5	Group 10	P-Value
Number Patients	405	100	-
Needle Whitacre Quincke	239 166	38 71	0.0001967 **
Position Puncture Lateral Decubitus Sitting	314 91	64 36	0.006801 **
Insertion Needle Median Paramedian	233 172	29 71	0.0000003496 **
CSF Presence	405	100	0.4423 **
Paresthesias: Yes(%)	23 (5.6%)	5 (%)	1.0000 **

\*\*: Fisher's exact test

**Table III: Characteristics in all groups in perioperative period (Mean±SD)**

Parameters	Group 7.5	Group 10	P-Value
Number Patients	405	100	-
Oncet sensitive block	0:58±0:10	0:58±0:10	0.8215 *
Time until T3 (min)	2:32±0:36	1:59±0:57	0.0000000052 *
Pneumoperitoneum (min)	36±11	35±8	0.8737 *
↑ Pneumoperitoneum	6 (1.4%)	2 (2%)	0.6608 **
Shoulder pain	29 (7.1%)	6 (6%)	0.8146 **
Rescue fentanyl	29 (7.1%)	6 (6%)	0.8146 **
Nauseas/Vomiting	0	0	-
Orogastric tube need	0	0	-
Hypoxemia	0	0	-
CO <sub>2</sub> retention	0	0	-
Table to stretcher	405	100	-
Duration motor block (h)	1:14±0:21	1:14±0:20	0.2397 *
Duration sensitive block (h)	2:45±0:27	2:38±0:27	0.01625 *

\*: Kruskal-Wallis test \*\*: Fisher's exact test

The frequency of shoulder pain occurred in 35 (6.9%) patients even after using the local anesthetic solution in the right diaphragmatic cup. Reflecting the need to use 50 µg of fentanyl in all these cases.

Paresthesia was observed in 28 (5.5%) of the thoracic punctures, 11 (2.1%) with the cut point needle and 17 (3.3%) with the pencil-point needle, without significant difference (p-value=0.5631).

The duration of the pain complaint after paresthesia in the thoracic puncture was not observed in none patients on the 1st, 3rd, and on the 7th postoperative day of evaluation. In this way, all paresthesias were transient and without residual sequelae. Three patients complained PDPH. There were no serious complications such epidural hematomas, infection, or permanent nerve injuries in all patients.

## Discussion

In this retrospective study of 505 patients undergoing TSA for LC, we demonstrated that low doses (7.5 mg and 10 mg) of 0.5% hyperbaric bupivacaine associated with prior intrathecal administration of 25 µg of fentanyl provided a longer-lasting sensory block than motor blockade, with low levels of pneumoperitoneum (8 mmHg), and the need to increase it in only eight (1.5%) patients, without the use of an orogastric tube and the ability to move from the table to the surgery table to the transport stretcher in all patients. The presence of cholecystitis in 40 (7.9%) patients and the abdomen with previous surgery of different types in 77 (15.2%) patients did not prevent the performance of LC through TSA, with excellent results.

The creation of the pneumoperitoneum is the essential component for laparoscopic procedures. The insufflation of gas into the peritoneal cavity increased intraabdominal pressure can cause several cardiocirculatory and pulmonary effects [8]. However, the study did not address the incidence of shoulder pain that is common in laparoscopic surgery. Shoulder pain and pain in the upper

abdomen are common complaints after laparoscopy, sometimes surpassing the pain at incision sites. The incidence of shoulder pain ranges from 35 to 80% [9]. A carbon dioxide pneumoperitoneum pressure lower than that usually utilized to perform laparoscopic surgery reduces both the frequency and intensity of shoulder-tip pain following LC [10]. In a recent systematic review and meta-analysis on the effect of intraperitoneal local anesthesia in LC submitted to GA, showed that the use of intraperitoneal local anesthesia (lidocaine, bupivacaine, levobupivacaine, ropivacaine) is safe, and it results in a statistically significant reduction in early postoperative abdominal pain, and improves shoulder pain during spinal anesthesia for LC [4-6, 11]. In this study, despite the use of local anesthetic in all cases immediately after insufflation of the pneumoperitoneum through 22G needle puncture, 35 (6.9%) patients required the use of fentanyl for shoulder pain relief.

The technique of spinal anesthesia with lumbar puncture compared to general anesthesia did not require any modification of the surgical technique, except for low flow insufflation (8 mmHg) and limitation of the total volume of CO<sub>2</sub> used for peritoneal insufflation to a maximum of 4 litres [12]. The use of low-pressure pneumoperitoneum (9 mmHg CO<sub>2</sub>) did not increase the duration of surgery, in addition to reducing shoulder pain [13]. In our study with TSA for LC, we used 8 mmHg CO<sub>2</sub> and there was only need to increase the pressure to 10 mmHg in eight (1.5%) and the dose of 7.5 or 10 mg of 0.5% hyperbaric bupivacaine did not influence the result.

In a study comparing 0.5% isobaric with hyperbaric bupivacaine at a fixed dose of 10 mg, performed with thoracic puncture between T9-T10 for orthopedic surgeries of the lower limb in 200 patients, showed that all patients developed spinal and there was no failure, and the solution did not affect the onset of the anesthesia [14]. However, the duration of the motor block was longer than the sensory block with the isobaric solution and, on the contrary, the sensory block was longer with the hyperbaric solution than the motor block, when injected in the lower thoracic region at the same dose and without opioids [14]. There was no difference in the incidence of hypotension or paresthesia and no neurological sequelae occurred [14]. In this study with 0.5% hyperbaric bupivacaine at doses of 7.5 and 10 mg for LC with low doses of pneumoperitoneum, it was shown that the dose did not alter the latency time in the lower thoracic region. And also that the use of 25 µg of fentanyl did not influence the latency of hyperbaric bupivacaine being injected separately.

Arterial hypotension can occur during spinal anesthesia for LC. In studies comparing SA with 15 mg of hyperbaric bupivacaine with GA, hypotension occurred in 41% of patients [12], 58% of patients, and 58.6% of patients [15,16]. Several studies have been performed comparing spinal anesthesia and lumbar puncture with 15 mg and thoracic spinal puncture with 7.5 mg of 0.5% hyperbaric bupivacaine for CL [5,17]. The incidence of arterial hypotension after lumbar puncture with 15 mg of 0.5% hyperbaric bupivacaine decreased from 32% [5] and 43.3% [17] to 15% [5] and 13% [17] with 7.5 mg of the same substance and thoracic puncture. Both studies showed that TSA provides better hemodynamic stability, vasopressor lesser use and early ambulation and discharge with higher degree of patient satisfaction making it excellent for day case surgery.

This study comparing 10 mg with 7.5 mg of hyperbaric bupivacaine in TSA showed that there was no significant difference between doses in the incidence of arterial hypotension (15% vs. 19%)



Shoulder pain during CL under spinal anesthesia occurs due to diaphragmatic irritation by CO<sub>2</sub>, with the C5 dermatome correlated with this pain. The pain in the shoulder can be severe enough to result in conversion to GA, and only one patient was converted to general anesthesia due to intolerable shoulder pain [18]. The incidence of right shoulder pain ranged from 13% [19] to 47% [12] requiring an additional dose of fentanyl. In 3,492 patients submitted to LSA for LC to shoulder pain incidence was 12.29%, with no need for conversion in any patient [20]. In this study with 505 patients submitted to TSA, local irrigation of the right diaphragm with 20 ml of 2% lidocaine or 0.25% bupivacaine decreased right shoulder pain incidence to 6.9%. It is essential for the reduction of shoulder pain that the local anesthetic is injected into the diaphragmatic cupula immediately after the creation of the pneumoperitoneum.

Paresthesias are relatively common during spinal needle insertion, both in the lumbar region and in the thoracic region. During puncture of the subarachnoid space with any type of needle, it is possible and perhaps more likely that paresthesias occur when the spinal needle makes contact with a nerve root within the subarachnoid space. Studying 104 patients during spinal needle insertion in the lumbar region and if paresthesia occurred, the needle was fixed in place and the stylet removed to observe if cerebrospinal fluid (CSF) flowed from the hub [21]. The presence of CSF was considered evidence that the needle had entered the subarachnoid space. Paresthesia occurred in 14/103 (13.6%) of the patients and one patient had paresthesia twice, with CSF being observed in 86.7% (13/15) of the time [21]. All paresthesias were transient.

Studying low thoracic puncture (T10-T11) in 300 patients with two different needles (Quincke x Whitacre) randomized into two groups of 150 patients undergoing elective surgery in the sitting or lateral position, showed that paresthesias occurred in 20/300 (6.6%) of patients [22]. Seven patients experienced paresthesia with Quincke needle compared with 13 patients with Whitacre, without statistical difference. All paresthesias were transient and without neurological sequelae. The paresthesias in 28 patients in this study after thoracic puncture were transient and disappeared in the immediate postoperative period.

## Conclusion

The present retrospective study with 505 patients confirmed that TSA with low doses of 0.5% hyperbaric bupivacaine associated with 20 µg of fentanyl is a safe technique for patients undergoing LC, with low pressure for performing pneumoperitoneum, without presenting any neurological complications. TSA provides hemodynamic stability with low need for vasopressors, without the appearance of hypoxemia or hypercarbia, without the need for an orogastric tube, and moving from the operating table to the stretcher without assistance, and with excellent analgesia for up to 6 hours and can be used on an outpatient basis.

In this study with 505 patients undergoing LC with TSA in the lower region, it was demonstrated that the use of hyperbaric bupivacaine and a Trendelenburg light position enhances the dispersion of hyperbaric solutions in the posterior region of the spinal canal (sensitive rootlets) with shorter duration of motor block (motor rootlets) and a longer sensory block. Giving TSA may provide another option for LC surgeries: improved patient safety, reduced postanesthesia care stay, and better postoperative pain relief.

From the several hospitals in Rio de Janeiro, São José do Rio Preto and João Pessoa – Brazil

## References

1. Dubois F, Icard P, Berthelot G, Levard H (1990) Coelioscopic cholecystectomy. *Annals Surgery* 211: 60-62.
2. Yu G, Wen Q, Qiu L, Bo L, Yu J (2015) Laparoscopic cholecystectomy under spinal anaesthesia vs. general anaesthesia: a meta-analysis of randomized controlled trials. *BMC Anesthesiology* 15: 176.
3. Ali Y, Nagui Elmasry M, Negmi H, Ouffi HÁ, Fahad B, et al. (2008) The feasibility of spinal anesthesia with sedation for laparoscopic general abdominal procedures in moderate risk patients. *M.E.J. Anesth* 19: 1027-1039.
4. Imbelloni LE, Sant'Anna R, Fornasari M, Fialho JC (2011) Laparoscopic cholecystectomy under spinal anesthesia: comparative study between conventional-dose and low-dose hyperbaric bupivacaine. *Local and Regional Anesthesia* 4: 41-46.
5. Imbelloni LE (2014) Spinal anesthesia for laparoscopic cholecystectomy: Thoracic vs. lumbar technique. *Saudi J Anesth* 8: 477-483.
6. Imbelloni LE (2014) Spinal anesthesia for laparoscopic cholecystectomy. *Review Article. Glob J Anesthesiol* 1: 101.
7. Imbelloni LE, Fornasari M, Sant'Anna R, Morais Filho GB (2022) Thoracic spinal anesthesia is safe and without neurological sequelae. Study with 1,406 patients. *Int J Anesthetic Anesthesiol* 9: 148.
8. Chui PT, Gin T, Oh TE (1993) Anaesthesia for laparoscopic general surgery. *Review. Anaesth Intens Care* 21: 163-171.
9. van Dijk JEW, Dedden SJ, Geomini PMAJ, Meijer P, van Hanegem N, et al. (2017) POStLaparoscopic Reduction of pain By combining intraperitoneal normal saline And the pulmonary Recruitment maneuver (POLAR BEAR trial). RCT to estimate reduction in pain after laparoscopic surgery when using a combination therapy of intraperitoneal normal saline and the pulmonary recruitment maneuver. *BMC Women's Health* 17: 42
10. Sarli L, Costi R, Sansebastiano G, Trivelli M, Roncoroni L (2000) Prospective randomized trial of low-pressure pneumoperitoneum for reduction of shoulder-tip pain following laparoscopy. *Br J Surgery* 87: 1161-1165.
11. Boddy AP, Mehta S, Rhodes M (2006) The effect of intraperitoneal local anesthesia in laparoscopic cholecystectomy: A systematic review and meta-analysis. *Anesth Analg* 103: 682-688.
12. Imbelloni LE, Fornasari M, Fialho JC, Sant'Anna R, Cordeiro JA (2010) General anesthesia versus spinal anesthesia for laparoscopic cholecystectomy. *Rev Bras Anesthesiol* 60: 217-227.
13. Sarli L, Costi R, Sansebastiano G, Trivelli M, Roncoroni L (2000) Prospective randomized trial for reduction of shoulder-tip pain following laparoscopy. *Br J Surg* 87: 1161-1165.
14. Imbelloni LE, Gouveia MA (2014) A comparison of thoracic spinal anesthesia with low-dose isobaric and low-dose hyperbaric bupivacaine for orthopedic surgery: A randomized controlled trial. *Anesth Essays Res* 8: 26-31.
15. Tzovaras G, Fafoulakis F, Pratsas K, Georgopoulou S, Stamatiou G, et al. (2008) Spinal vs general anesthesia for laparoscopic cholecystectomy: interim analysis of a controlled randomized trial. *Arch Surg* 143: 497-501.
16. Yuksek YN, Akat AZ, Gozalan U, Daglar G, Pala Y, et al.

- 
- (2008) Laparoscopic cholecystectomy under spinal anesthesia. *Am J Surg* 195: 533-536.
17. Yousef GT, Lasheen AE (2012) General anesthesia versus segmental thoracic or conventional lumbar spinal anesthesia for patients undergoing laparoscopic cholecystectomy. *Anesth Essays Res* 6: 167-173.
  18. Hamad MA, El-Khattary AO (2003) Laparoscopic cholecystectomy under spinal anesthesia with nitrous oxide pneumoperitoneum: a feasibility study. *Surg Endosc* 17: 1426-1428.
  19. Tzoravaras G, Fafoulakis F, Pratsas K, Georgopoulou S, Stamatiou G, et al. (2006) Laparoscopic cholecystectomy under spinal anesthesia. A pilot study. *Surg Endosc* 20: 580-582.
  20. Sinha R, Gurwara AK, Gupta SC (2009) Laparoscopic cholecystectomy under spinal anesthesia: A study of 3492 patients. *J Laparoendosc Adv Surg Tech A* 19: 323-327.
  21. Pong RP, Gmelch BS, Bernards CM (2009) Does paresthesia during spinal needle insertion indicate intrathecal needle placement? *Reg Anesth Pain Med* 34: 29-32.
  22. Imbelloni LE, Pitombo PF, Ganem EM (2010) The incidence of paresthesia and neurologic complications after lower spinal thoracic puncture with cut needle compared to pencil point needle. Study in 300 patients. *J Anesth Clin Res* 1: 106.